

## Hepatoprotective effect of the ethyl acetate extract of *Teucrium polium* L. against carbontetrachloride-induced hepatic injury in rats

TATJANA KADIFKOVA PANOVSKA<sup>1</sup>  
SVETLANA KULEVANOVA<sup>2</sup>  
ICKO GJORGOSKI<sup>3</sup>  
MIRJANA BOGDANOVA<sup>4</sup>  
GORDANA PETRUSHEVSKA<sup>5</sup>

<sup>1</sup>*Institute of Toxicology  
Faculty of Pharmacy  
University »Ss. Cyril and Methodius«  
1000 Skopje, Republic of Macedonia*

<sup>2</sup>*Institute of Pharmacognosy  
Faculty of Pharmacy  
University »Ss. Cyril and Methodius«  
1000 Skopje, Republic of Macedonia*

<sup>3</sup>*Institute of Biology  
Faculty of Natural Sciences and Mathematics  
University »Ss. Cyril and Methodius«  
P. B. 126, 1000 Skopje  
Republic of Macedonia*

<sup>4</sup>*Institute of Clinical Biochemistry  
Clinical Center, 1000 Skopje  
Republic of Macedonia*

<sup>5</sup>*Institute of Pathology  
Faculty of Medicine  
University »Ss. Cyril and Methodius«  
1000 Skopje, Republic of Macedonia*

Hepatoprotective activity of the ethyl acetate extract of *Teucrium polium* L. was investigated using rats with CCl<sub>4</sub>-induced liver damage. Specific biochemical parameters (glutathione peroxidase, superoxide dismutase, reduced glutathione and total antioxidative status) were estimated in blood and in liver homogenate. Lipid peroxidation in CCl<sub>4</sub>-intoxicated rats was evidenced by a marked increment in the levels of thiobarbituric acid reactive substances. Histopatological examinations of the liver were undertaken to monitor the liver status. Silymarin was used as a standard to compare the hepatoprotective activity of the extract. Some biochemical parameters in groups treated with the *Teucrium polium* extract at a dose of 25 mg kg<sup>-1</sup>, showed significantly different values than that of the CCl<sub>4</sub>-treated group. The liver biopsy of all experimental rat groups treated with the *Teucrium polium* ethyl acetate extract showed significant restoration of the normal histomorphological pattern of liver cells. The study substantiates the potential hepatoprotective activity of the ethyl acetate extract of *Teucrium polium* L.

**Keywords:** *Teucrium polium* (Lamiaceae), hepatoprotective effect, carbon tetrachloride, silymarin, glutathione

Accepted March 5, 2007

\* Correspondence, e-mail: taka@ff.ukim.edu.mk

Ample experimental and epidemiological studies support the involvement of oxidative stress in the pathogenesis and progression of several chronic diseases (1). Oxygen, indispensable for maintaining life, sometimes becomes toxic, resulting in the generation of most aggressive agents such as reactive oxygen species (ROS). Aerobic organisms employ a battery of defense mechanisms such as antioxidant enzymes superoxide dismutase (SOD), catalase and glutathione peroxidase (GPx) to prevent or mitigate oxidative tissue damage (2). SOD removes the superoxide radical to prevent formation of the hydroxyl radical. Catalase deals effectively with a large amount of hydrogen peroxide generated in peroxisomes. GPx is capable not only of utilizing hydroperoxides but also of metabolizing hydrogen peroxide in both the cytosolic and mitochondrial compartments. When the liver cell plasma membrane is damaged, many of the enzymes normally located in the liver cell cytosol are released into the blood stream. Their estimation in the blood is a useful quantitative marker of the extent and type of hepatocellular damage (3). Perturbation of the GSH status of a biological system has been reported to increase the lipid peroxidation (4). Thiobarbituric acid reactive substances, TBARS, are produced as by-products of lipid peroxidation that occurs in the hydrophobic core of biomembranes (5). At other sites, intake of compounds that induce antioxidant enzyme activity or scavenging of free radicals prevent oxidative damage (6).

*Teucrium polium* L. has been long recognized in folk medicine in the treatment of many pathophysiological conditions, such as gastrointestinal disorders, inflammations, diabetes and rheumatism. Its extract has been shown to induce hypotensive (7), anti-inflammatory (8), hypoglycemic (9), antispasmodic (10), antibacterial and antipyretic (11) effects. Most of these effects have been related to the antioxidant and free radical scavenging properties of *Teucrium polium* (12). In our previous studies, the diethyl ether, ethyl acetate and *n*-butanol extracts from *Teucrium* species were shown to possess significant free radical scavenging, hydroxyl radical scavenging and antioxidant activities *in vitro* (13). These *T. polium* extracts were also shown to inhibit lipid peroxidation in rat liver microsomes (14).

The present investigation was carried out to examine whether the *Teucrium polium* ethyl acetate extract might also have a protective effect against carbon tetrachloride (CCl<sub>4</sub>) induced hepatotoxicity *in vivo*. The exact mechanism of hepatotoxicity of CCl<sub>4</sub> is unclear, most probably resulting from a toxic intermediary that binds covalently to hepatocytes and causes a centrilobular hepatic necrosis. It has been established that CCl<sub>4</sub> is accumulated in hepatic parenchyma cells and metabolically activated by cytochrome P-450 dependent monooxygenases to form a trichloromethyl free radical (CCl<sub>3</sub>·). The latter alkylates cellular proteins and other macromolecules with a simultaneous attack on polyunsaturated fatty acids in the presence of oxygen to produce lipid peroxides leading to liver damage (15).

Alternate explanations of necrosis are lipid peroxidation and oxidation of thiol groups (16). CCl<sub>4</sub>-intoxication in rats is the experimental model widely used to study necrotic and steatotic changes in hepatic tissue. Accordingly, our experiment was designed to use rats with CCl<sub>4</sub>-intoxicated liver as a model.

In our work we examined the possible hepatoprotective effect of *Teucrium polium* ethyl acetate extract in CCl<sub>4</sub>-intoxicated rats. To assess the degree of liver damage we estimated some biochemical parameters in blood and in liver homogenates and performed histopathological liver examinations.

## EXPERIMENTAL

*Teucrium polium ethyl acetate extract.* – Aerial parts of *Teucrium polium* L. were collected in the early stages of vegetation from the Lazaropole district, Macedonia, during the summer of 2001. Voucher specimens were deposited at the Herbarium of the Institute of Pharmacognosy, Faculty of Pharmacy, Skopje (Macedonia). The ethyl acetate extract of *Teucrium polium* was prepared according to the procedure previously reported (13).

*Reagents.* – Reagents for antioxidant enzyme assays were purchased from Sigma Chem. Co. (USA). Kits RANSEL (RS504), RANSOD (SD125) and TAS (N 2332) for determination of the activity of glutathione peroxidase and superoxide dismutase as well as total antioxidative status (TAS), respectively, were purchased from Randox Laboratories Ltd. (UK). Sylimarin as the reference hepatoprotective drug was obtained from Extrasynthese (France). All other chemicals were of reagent grade and were used without further purification.

*Animals and experimental protocol.* – Female Wistar albino rats, 4–6 weeks, 180–230 g, were divided into 6 groups of 8 animals each. They were housed in an air-conditioned room at  $23 \pm 3$  °C,  $55 \pm 5\%$  humidity, 12-h light and were supplied with standard diet and water *ad libitum*, one week before and during the experimental period.

All drugs were injected into animals *i.p.* once daily. Group 1 served as a control group, receiving normal saline only ( $10 \text{ mL kg}^{-1}$ ) for 7 days; group 2 received  $\text{CCl}_4$  ( $3 \text{ mL kg}^{-1}$  50% in olive oil) on the 7th day; group 3 received the reference drug, sylimarin ( $25 \text{ mg kg}^{-1}$  in 50% ethanol) once daily for 7 days; group 4 received sylimarin during 7 days and  $\text{CCl}_4$  on the 7th day in the above mentioned dose; group 5 received ethyl acetate extract of *Teucrium polium* ( $25 \text{ mg kg}^{-1}$  in 50% ethanol) once daily for 7 days; group 6 received ethyl acetate extract of *Teucrium polium* once daily for 7 days and  $\text{CCl}_4$  on the 7th day in above mentioned doses.

On the 8th day, *i.e.*, 24 hours after  $\text{CCl}_4$  administration, the animals were sacrificed and their blood was collected to estimate GPx, SOD and TAS while the liver tissues were processed for homogenate preparation and histopathological examination.

*Liver homogenate.* – The animals were sacrificed by cervical dislocation and their livers were exposed, dissected free from extraneous tissues, rinsed with chilled 1.15% KCl solution (pH 7.0) and a 50% homogenate was prepared in  $0.15 \text{ mol L}^{-1}$  sodium phosphate buffer (pH 7.0). The homogenate was centrifuged at  $3500 \times g$  for 10 minutes at 4 °C and the supernatant was used for the estimation of the GSH content and lipid peroxide level.

*Hepatotoxicity.* – The activities of hepatic marker enzymes (GPx and SOD) and biochemical parameter TAS were assayed in blood using standard kits. Colorimetric estimation of reduced glutathione (GSH) in blood and in liver homogenate was performed as described by Beutler *et al.* (17). To a sample of liver homogenate, sulfosalicylic acid was added to precipitate the protein content. Then, the sample was centrifuged at  $1000 \times g$  and Ellman's reagent was added to the supernatant to form a stable color, which was then measured at 412 nm. Results were expressed as  $\text{mmol L}^{-1}$  using the molar absorption coefficient of the chromofore of  $1.36 \times 10^4 \text{ L mol}^{-1} \text{ cm}^{-1}$ .

The quantitative measurement of lipid peroxidation was done by measuring the concentration of thiobarbituric acid reactive substances (TBARS) in liver homogenate using the method of Ohkawa *et al.* (18). The amount of malondialdehyde (MDA) formed

was quantitated by the reaction with thiobarbituric acid and used as an index of lipid peroxidation. The results were expressed as nmol MDA mg<sup>-1</sup> protein. The content of protein was determined according to the method of Bradford using bovine serum albumin as a standard (19).

*Histopathological examination.* – Animals were sacrificed on the day of blood sampling; the liver was removed, sliced and washed in saline. Liver pieces were preserved in 10% formaldehyde solution for the histopathological study. The liver pieces were processed and embedded in paraffin wax. Slices, 4–6 μm thick, were stained with hematoxylin and eosin and photographed.

*Statistical analysis.* – Results are expressed as mean ± SD. Statistical differences between CCl<sub>4</sub> and test groups were determined using Student's *t*-test.

## RESULTS AND DISCUSSION

The results on the effects of *Teucrium polium* ethyl acetate extract on the rats with liver-injury induced by CCl<sub>4</sub> are summarized in Table I. The results indicate that twenty-four hours after CCl<sub>4</sub> administration there was a slight increase in blood GPx (43.72 U mL<sup>-1</sup>) compared to the control group (36.15 U mL<sup>-1</sup>). In the groups where sylimarin was given, the levels of GPx (3.42 U mL<sup>-1</sup>) were significantly lower (*p* < 0.05) than in the CCl<sub>4</sub>-treated group. The levels of SOD (40 U mL<sup>-1</sup>) and TAS (1.13 U mL<sup>-1</sup>) were significantly (*p* < 0.05) reduced after intoxication with CCl<sub>4</sub>. Acute exposure to a single intraperitoneal dose of CCl<sub>4</sub> resulted in a severe decrease of GSH content both in blood (0.038

Table I. Effects of different treatments of rats on the specific activities of liver and blood biochemical parameters<sup>a</sup>

Group	GPx (U mL <sup>-1</sup> )	SOD (U mL <sup>-1</sup> )	TAS (mmol L <sup>-1</sup> )	GSH – blood (mmol L <sup>-1</sup> )	GSH – homogenate (mmol L <sup>-1</sup> )	TBARS – homogenate (nmol MDA mg protein <sup>-1</sup> )
1 – Control (NaCl)	36.15 ± 6.48	462 ± 20	0.73 ± 0.03	0.120 ± 0.016	3.90 ± 0.08	3.20 ± 0.10
2 – CCl <sub>4</sub> - olive oil	43.72 ± 2.86	40 ± 13	1.13 ± 0.23	0.038 ± 0.024	1.44 ± 1.17	4.03 ± 0.28
3 – Sylimarin	3.42 ± 2.03 <sup>b</sup>	308 ± 27 <sup>b</sup>	0.64 ± 0.09 <sup>b</sup>	0.115 ± 0.023 <sup>b</sup>	2.88 ± 0.76 <sup>b</sup>	2.45 ± 0.15 <sup>b</sup>
4 – Sylimarin + CCl <sub>4</sub>	3.59 ± 2.07 <sup>b</sup>	304 ± 30 <sup>b</sup>	0.62 ± 0.11 <sup>b</sup>	0.108 ± 0.021 <sup>b</sup>	2.50 ± 1.27 <sup>b</sup>	2.53 ± 0.23 <sup>b</sup>
5 – <i>T. polium</i>	40.04 ± 2.22 <sup>b</sup>	438 ± 43 <sup>b</sup>	0.49 ± 0.03 <sup>b</sup>	0.091 ± 0.012 <sup>b</sup>	1.33 ± 0.57	2.43 ± 0.49 <sup>b</sup>
6 – <i>T. polium</i> + CCl <sub>4</sub>	41.76 ± 2.26	394 ± 44 <sup>b</sup>	0.62 ± 0.18 <sup>b</sup>	0.081 ± 0.015 <sup>b</sup>	1.00 ± 0.21	3.12 ± 0.05 <sup>b</sup>

<sup>a</sup> Mean ± SD, *n* = 8.

<sup>b</sup> Statistically significant difference *vs.* CCl<sub>4</sub> group (*p* < 0.05).

GPx – glutathione peroxidase, SOD – superoxide dismutase, TAS – total antioxidative status, GSH – reduced glutathione, TBARS – thiobarbituric acid-reactive substances.

mmol L<sup>-1</sup>) and in liver homogenate (1.44 mmol L<sup>-1</sup>) to 32% and 37% of normal values, respectively. The depletion of GSH by CCl<sub>4</sub> was associated with an increase in lipid peroxidation as measured by the level of TBARS (4.03 nmol MDA mg protein<sup>-1</sup>) in liver homogenate. Administration of silymarin or *Teucrium polium* extract for 7 consecutive days afforded different degrees of protection against such depletion (Table I). The most significant protection effect was found at the level of SOD (from 40 to 394 U mL<sup>-1</sup>), TAS (from 1.13 to 0.62 mmol L<sup>-1</sup>) and TBARS (from 4.03 to 3.12 nmol MDA mg protein<sup>-1</sup>). Pretreatment with *Teucrium polium* extract did not prove almost any protective activity on the GPx level (41.76 U mL<sup>-1</sup>) against CCl<sub>4</sub> (43.72 U mL<sup>-1</sup>) intoxication. No protection related to GSH in homogenate (1.00 *vs.* 1.44 mmol L<sup>-1</sup>) was shown and only partial protection related to GSH in blood (0.081 *vs.* 0.038 mmol L<sup>-1</sup>) was evidenced during the pretreatment. The effect of *Teucrium polium* extract was quite close to that of silymarin only on the level of TBARS bases and the TAS value.

This protective effect of *Teucrium polium* ethyl acetate extract was confirmed by histological examination (Fig. 1). Hystopathological study of the control group liver (Fig. 1a) showed a normal hepatic architecture. Massive fatty changes, gross necrosis, broad infiltration of lymphocytes and of Kupffer cells around the central vein and loss of cellular boundary (Fig. 1b) were observed in the livers of CCl<sub>4</sub>-treated rats. In the groups pre-

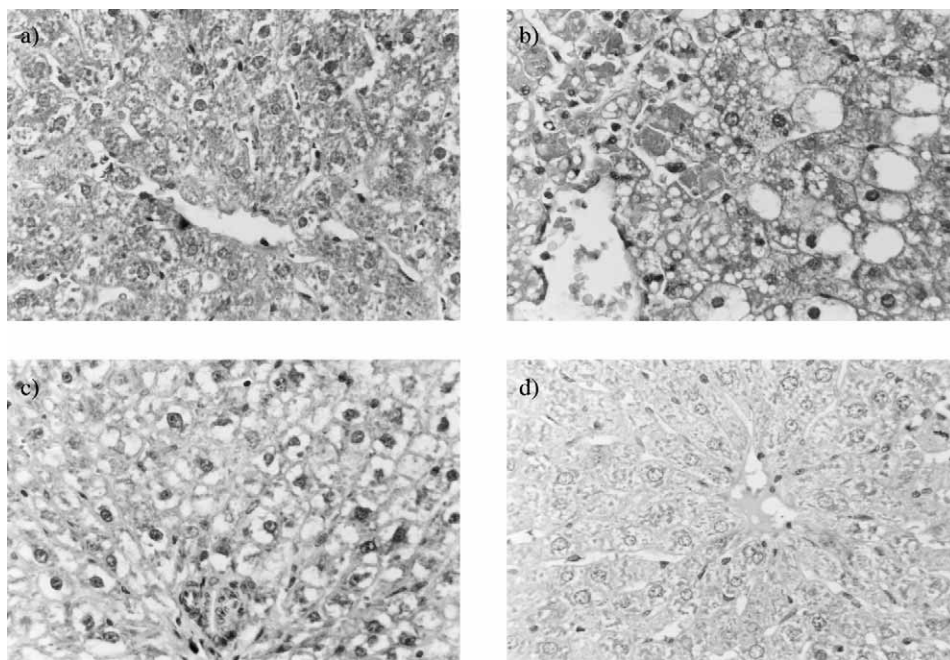


Fig. 1. Photomicrographs of rat liver slices. Groups of rats: a) group 1, control (NaCl for 7 days); b) group 2, CCl<sub>4</sub>-olive oil (3 mL kg<sup>-1</sup> on the 7<sup>th</sup> day); c) group 4, silymarin (25 mg kg<sup>-1</sup> for 7 days, CCl<sub>4</sub>, as above on the 7<sup>th</sup> day); d) group 6, *Teucrium polium* extract (25 mg kg<sup>-1</sup> for 7 days, CCl<sub>4</sub>, as above on the 7<sup>th</sup> day).

treated with sylimarin or *Teucrium polium* extract (Figs. 1c and 1d), the livers exhibited an almost normal architecture, with the presence of double nucleus hepatocytes, except for a slight deformity of hepatocytes with pyknosis and clearing of cytoplasm.

In our work, the CCl<sub>4</sub>-mediated hepatotoxicity was taken as the experimental model for liver injury. By estimating the activities of blood marker enzymes (GPx and SOD) and other biochemical parameters (TAS, GSH and TBARS), an assessment of the liver function can be made. The changed activities of these marker enzymes observed in CCl<sub>4</sub>-treated rats in our study correspond to the extent of liver damage induced by the toxin. The tendency of these enzymes to return towards a near normal level in groups treated with sylimarin or *Teucrium polium* ethyl acetate extract is a clear manifestation of their anti-hepatotoxic effect. Decline in GSH content in the liver of CCl<sub>4</sub>-intoxicated rats, and its subsequent return towards near normalcy in sylimarin and in *Teucrium polium* extract treated rats reveal the antioxidant effect of *T. polium*. Explanation of the possible mechanism underlying the hepatoprotective properties of the *Teucrium polium* extract includes the prevention of GSH depletion and destruction of free radicals (20). These two factors are believed to attribute to the hepatoprotective properties of *Teucrium polium*.

Elevated levels of TBARS observed in CCl<sub>4</sub>-treated rats indicate excessive formation of free radicals and activation of the lipid peroxidation system, resulting in hepatic damage. The significant decline in the concentration of these constituents in the liver homogenate of sylimarin and *Teucrium polium* extract administered rats indicates anti-lipid peroxidative effect of *T. polium*.

A comparative histopathological study of livers from different experimental groups further corroborated the hepatoprotective efficacy of *T. polium*.

## CONCLUSIONS

This study has demonstrated a potential liver protective effect of the *Teucrium polium* ethyl acetate extract as well as potential anti-lipid peroxidative and antioxidant activities in rats with CCl<sub>4</sub>-induced hepatotoxicity.

Further research is needed to isolate and purify the active principle involved in hepatoprotection of this plant as well as to confirm the mechanisms responsible for hepatoprotective activity.

## REFERENCES

1. T. Sunita, V. Vupta and B. Sandeep, Comparative study of antioxidant potential of tea with and without additives, *Indian. J. Physiol. Pharmacol.* 44 (2000) 215–219.
2. B. Halliwell and J. M. C. Gutteridge, *Free Radicals in Biology and Medicine*, 2<sup>nd</sup> ed., Oxford University Press, Oxford 1989, pp. 78–93.
3. S. K. Mitra, M. V. Venkataranganna, R. Sudaram and S. Gopumadhavan, Protective effect of HD-03, a herbal formulation, against various hepatotoxic agents in rats, *J. Ethnopharmacol.* 63 (1998) 181–186; DOI: 10.1016/S0378-8741(98)00088-9.

4. B. Uday, D. Das and K. R. Banerjee, Reactive oxygen species: Oxidative damage and pathogenesis, *Curr. Sci.* **77** (1999) 658–666.
5. C. Fraga, B. Leibovitz and A. Tappel, Halogenated compounds as inducers of lipid peroxidation in tissue slices, *Free Rad. Biol. Med.* **3** (1987) 119–123.
6. P. Hochstein and A. S. Atallah, The nature of oxidants and antioxidant systems in the inhibition of mutation and cancer, *Mutation Res.* **202** (1988) 363–375; DOI: 10.1016/0027-5107(88)90198-4.
7. M. S. Suleiman, A. S. Abdul-Ghani, S. Al-Khalil and R. Amin, Effect of *Teucrium polium* boiled leaf extract on intestinal motility and blood pressure, *J. Ethnopharmacol.* **22** (1988) 111–116; DOI: 10.1016/0378-8741(88)90236-X.
8. M. Tariq, A. M. Ageel and M. S. Al-Said, Antiinflammatory activity of *T. polium*, *Int. J. Tissue React.* **11** (1989) 185–188.
9. M. N. Gharaibeh, H. H. Elayan and A. S. Salhab, Hypoglycemic effects of *Teucrium polium*, *J. Ethnopharmacol.* **24** (1988) 93–99; DOI: 10.1016/0378-8741(88)90139-0.
10. Z. Yaniv, A. Dafni, J. Friedman and D. Palevitch, Plants used for the treatment of diabetes in Israel, *J. Ethnopharmacol.* **19** (1987) 145–151; DOI: 10.1016/0378-8741(87)90038-9.
11. G. Autore, F. Capasso, R. De Fusco, M. P. Fasulo, M. Lembo, N. Mascolo and A. Menghini, Antipyretic and antibacterial actions of *Teucrium polium* (L.), *Pharmacol. Res. Commun.* **16** (1984) 21–29; DOI: 10.1016/S0031-6989(84)80101-0.
12. G. Ilhami, U. Metin, O. Munir, B. Suktru and K. Irfan, Antioxidant and antimicrobial activities of *Teucrium polium* L., *J. Food Technol.* **1** (2003) 9–16.
13. T. Kadifkova Panovska, S. Kulevanova and M. Stefova, *In vitro* antioxidant activity of some *Teucrium* species (*Lamiaceae*), *Acta Pharm.* **55** (2005) 207–214.
14. T. Kadifkova Panovska and S. Kulevanova, Effect of some *Teucrium* species (*Lamiaceae*) on lipid peroxidation in rat liver microsomes, *Fresenius Environ. Bull.* **14** (2005) 957–959.
15. R. O. Recknagel, A new direction in the study of carbon tetrachloride hepatotoxicity, *Life Sci.* **33** (1983) 401–408; DOI: 10.1016/0024-3205(83)90787-7.
16. M. J. Ellenhorn, *Ellenhorn's Medical Toxicology: Diagnosis and Treatment of Human Poisoning*, 2<sup>nd</sup> ed., Williams and Wilkins Publications, Los Angeles 1997.
17. E. Beutler, O. Duron and B. M. Kelly, Improved method for the determination of blood glutathione, *J. Lab. Clin. Med.* **61** (1963) 882–888.
18. H. Ohkawa, N. Ohishi and K. Yagi, Assay for lipid peroxides in animal tissue by thiobarbituric acid reaction, *Anal. Biochem.* **95** (1979) 351–358; DOI: 10.1016/0003-2697(79)90738-3.
19. M. M. Bradford, A rapid and sensitive method for the quantification of microgram quantities of protein utilizing the principle of protein dye binding, *Anal. Biochem.* **72** (1976) 248–254; DOI: 10.1016/0003-2697(76)90527-3.
20. A. Valenzuela, C. Lagos, K. Schmidt and K. Videla, Sylmarin protection against hepatic lipid peroxidation induced by acute ethanol intoxication in the rat, *Biochem. Pharmacol.* **3** (1985) 2209–2212. DOI: 10.1016/0006-2952(85)90421-6.

## S A Ž E T A K

### Hepatoprotektivni učinak etil-acetatnog ekstrakta biljke *Teucrium polium* L. na jetru štakora oštećenu tetraklormetanom

TATJANA KADIFKOVA PANOVSKA, SVETLANA KULEVANOVA, ICKO GJORGOSKI,  
MIRJANA BOGDANOVA i GORDANA PETRUSHEVSKA

Hepatoprotektivno djelovanje etil-acetatnog ekstrakta biljke *Teucrium polium* L. ispitivano je na štakorima čija je jetra oštećena tetraklormetanom. Specifični biokemijski parametri (glutation peroksidaza, superoksid dismutaza, reducirani glutation i ukupni antioksidativni status) procijenjeni su u krvi i homogenatu jetre. Lipidna peroksidacija u štakora intoksiciranih tetraklormetanom dokazana je povećanjem koncentracije reaktivnih derivata tiobarbiturne kiseline. Stanje jetre procijenjeno je histopatološkim ispitivanjima. U ispitivanjima hepatoprotektivnog djelovanja ekstrakta *Teucrium polium* upotrebljen je silimarin kao standard. Neki biokemijski parametri u skupini životinja tretiranih ispitivanim ekstraktom u dozi od 25 mg kg<sup>-1</sup> imali su značajno različite vrijednosti od skupine tretirane s CCl<sub>4</sub>. Biopsija jetre u svim ispitivanim životinjama tretiranim ekstraktom pokazala je uspostavu normalnih histomorfoloških uvjeta u stanicama, što ukazuje na hepatoprotektivno djelovanje biljke *Teucrium polium*.

*Ključne riječi:* *Teucrium polium* Lamiaceae, hepatoprotektivni učinak, tetraklormetan, silimarin, glutation

*Institute of Toxicology and Institute of Pharmacognosy, Faculty of Pharmacy, University »Ss. Cyril and Methodius«, 1000 Skopje, Republic of Macedonia*

*Institute of Biology, Faculty of Natural Sciences and Mathematics, University »Ss. Cyril and Methodius«, 1000 Skopje, Republic of Macedonia*

*Institute of Clinical Biochemistry, Clinical Center, 1000 Skopje, Republic of Macedonia*

*Institute of Pathology, Faculty of Medicine, University »Ss. Cyril and Methodius«, 1000 Skopje Republic of Macedonia*